

Combining laser and ultrasound technologies to deliver platelet-rich plasma

Abstract

Combination therapies are often used by aesthetic practitioners to achieve the best possible results for their patients. Although laser therapies can produce good results when treating common skin conditions, ultrasound technologies can be used to push particles from one place to another. Platelet-rich plasma (PRP) treatment is also one of many injectable procedures available for the purposes of skin rejuvenation and revitalisation. This paper describes a case report of a 47-year-old woman who was treated with needle-free PRP, minor fractional laser treatment and an ultrasound probe. A carbon dioxide (CO₂) laser was used to create perforations, PRP was applied topically to the skin, and then an ultrasound probe was used to force the PRP from the skin surface into the dermis. As PRP was administered without a needle, the procedure was performed without causing any post-procedure bruising. The patient was pleased with the treatment outcomes and the quality of her skin improved significantly.

Key words

▶ Platelet-rich plasma ▶ Laser ▶ Ultrasound ▶ Combination therapy

Medical technologies are continuously improving and combination therapies are often used by aesthetic practitioners to give patients the results they want to achieve. Whereas laser therapies exist for the treatment of skin conditions (Papadavid and Katsambas, 2003), ultrasound technology can be used to push particles from one place to another (Issa, 2013) and platelet-rich plasma (PRP) is one of many injectable treatments offered by aesthetic practitioners for the purpose of skin rejuvenation injections (Redaelli, 2010).

This article is a case report of a 47-year-old woman who had needle-free PRP combined with minor fractional laser treatment for the purpose of skin rejuvenation. A carbon dioxide (CO₂) laser was used to create skin perforations, PRP was applied topically

using sterile gloves and an ultrasound probe forced the PRP from the skin surface into the dermis. As PRP was administered without a needle, there was no risk of post-procedure bruising. Both the patient and clinician were pleased with the treatment outcomes and saw objective and subjective improvements to the quality of her skin.

Treatment modalities for skin damage and dermal rejuvenation Laser

Of the many different lasers available, the CO₂ laser is one which is known as ablative. Laser is an acronym for light amplification by the stimulation of electromagnetic radiation (Carroll and Humphreys, 2006); therefore, the CO₂ laser produces an intense beam of photons by exciting CO₂ to produce infrared light (Ross et al, 1999). The infrared light produced is of one wavelength only, which differentiates lasers from an intense pulsed light (IPL) system, which produces a bright light comprised of many different wavelengths (Hedelund et al, 2006).

Whereas some lasers cause skin or tissue ablation (such as Erbium YAG lasers and CO₂ lasers), others are non-ablative (such as Nd:YAG and Alexandrite lasers) (Alexiades-Armenakas et al, 2008). Following CO₂ laser treatment, a wound is created owing to a loss of epithelium (Ross et al, 1999). Wound healing subsequently takes place from unablated epithelium over a period of several weeks (Ross et al, 1999). During this time, epithelial elements in the dermis, including hair follicles, apocrine glands, eccrine glands and epithelial elements at the reticular-papillary dermis junction, multiply to re-epithelialise the skin (Martin, 1997). This is why the skin can often be red for a few months following CO₂ laser resurfacing.

Common technology built into CO₂ lasers enables the beam to be fractionated. This means that, instead of ablating the whole surface of the skin, the laser is fired in an array of dots, causing ablation of the areas treated, but leaving areas of normal skin surrounding the ablated skin. This leads to faster wound healing, as healing by secondary intention and wound contraction also occur by multiplication of the remaining epithelial elements within the skin (Martin, 1997). Fractionated CO₂ laser treatment, therefore, leads to a more rapid



TAIMUR SHOAIB

Taimur Shoaib, Consultant Plastic Surgeon, La Belle Forme,
24-26 Wilson Street, Glasgow
e: office@shoaib.co.uk

CASE STUDY ▼

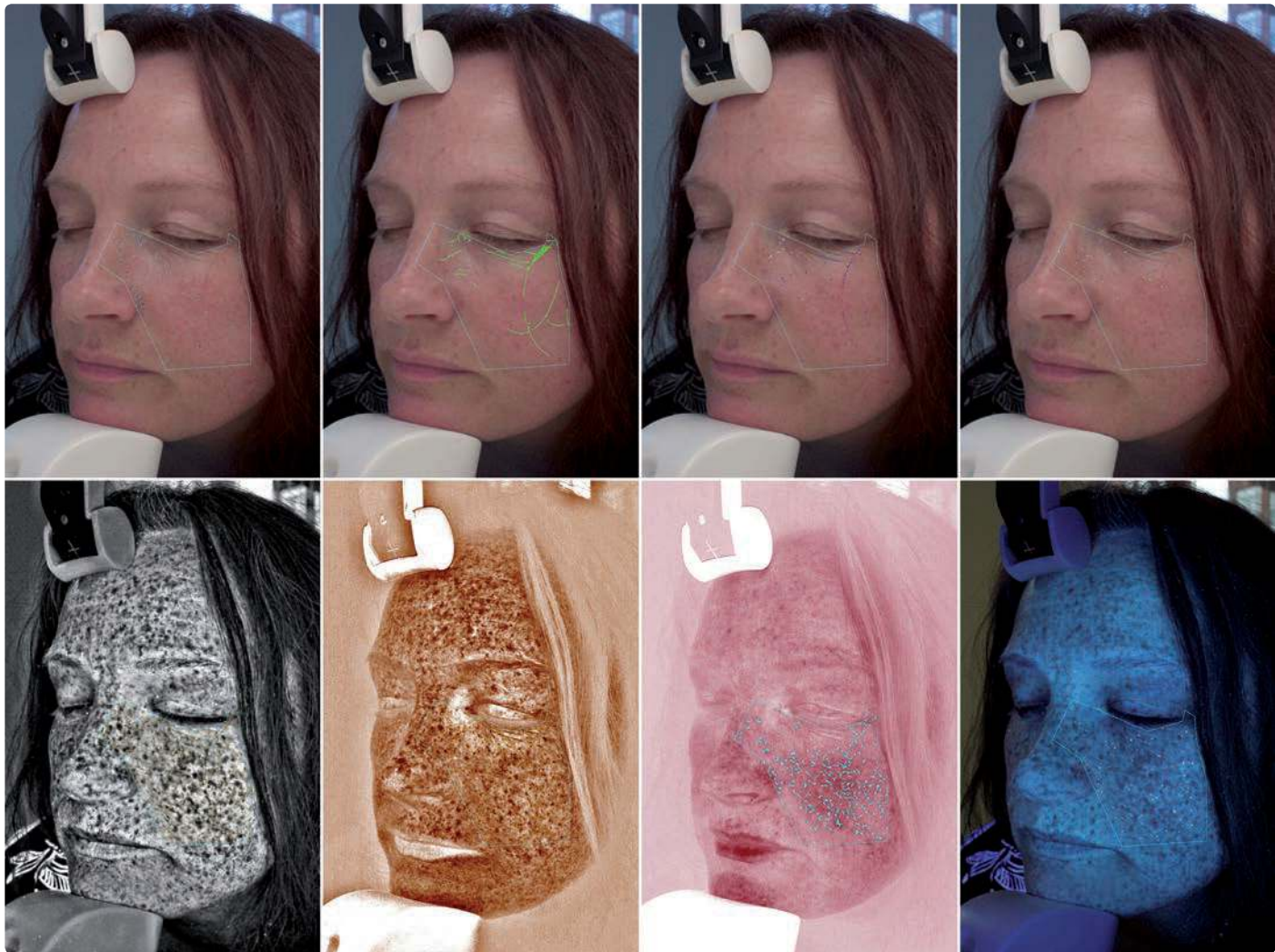


Figure 1: VISIA scan before treatment, showing spots, wrinkles, texture, pores, UV spots, brown spots, red areas and porphyrins (from left to right, first row to second row)

recovery post procedure (Alexiades-Armenakas et al, 2008). The recovery rate depends on the depth of ablation, power settings of the laser, diameter of each dot, distance between subsequent dots, and the length of time the laser beam is in contact with the skin.

Indications and contraindications

CO₂ laser resurfacing is indicated for the treatment of acne scarring, epidermal hyperplasia, fine lines and wrinkles, surface ablation of rhinophyma, stretch marks and sun-damaged skin. Contraindications include active skin infection, a predisposition to keloid scars, taking isotretinoin (Roaccutane) within the previous six months, thinned skin in the region to be treated and a tendency for poor healing.

Ultrasound

Ultrasound has been used in medical practice for many decades and is now used for imaging and treatment (Newman and Rozycki, 1998). Treatment options with

ultrasound include external and/or internal fat cell ablation, and can also be used to push particles into the skin through pores created by an appropriate skin penetration system (Issa, 2013). A fractionated CO₂ laser could be such a system; however, equally, skin perforations can be created by micro needling or an Erbium laser (Alexiades-Armenakas et al, 2008).

In his clinic, the clinician uses an ultrasound head with IMPACT technology (ABC Lasers, Cambridge), which is part of the iPixel CO₂ laser. The laser has two heads: one of which is the CO₂ laser and the other is the IMPACT ultrasound head. The ultrasound head is designed to deliver mesotherapy following fractional ablation treatment with the CO₂ laser and is a proven technology for the delivery of products to the dermis (Gold, 2012).

Indications and contraindications

The use of ultrasound with the IMPACT head has not been fully established as a treatment option in

Table 1: VISIA scan results
(high percentages indicate the approximate centile for the patient's age and sex for the analysed variable)

Before treatment	After treatment
Spots, 82%	Spots, 96%
Wrinkles, 66%	Wrinkles, 96%
Texture, 97%	Texture, 99%
Pores, 97%	Pores, 99%
UV spots, 22%	UV spots, 45%
Brown spots, 9%	Brown spots, 56%
Red areas, 38%	Red areas, 49%
Porphyrins, 42%	Porphyrins, 63%

medical aesthetics. Ultrasound is indicated to deliver a topical product into the dermis; however, since the technology is new, there are no published or reported contraindications for treatment.

Platelet-rich plasma

PRP injections are increasing in popularity as a method of skin rejuvenation, which involves taking a blood sample and centrifugation of the blood to separate its components. The platelet layer is then harvested and infused into the skin and the platelets degranulate, releasing growth factors. Growth factors are necessary for wound healing, repair and inflammation, all of which are important processes for tissue regeneration (Martin, 1997). Since growth factors heal tissues, the theory is that PRP will rejuvenate the skin. When growth factors are released, this leads to a cascade of activity, which results in cellular and tissue repair, and is also thought to rejuvenate the skin when injected (Rozman and Bolta, 2007). Growth factors released following degranulation of platelets include platelet-derived growth factor, transforming growth factor beta, fibroblast growth factor, insulin-like growth factor types 1 and 2, vascular endothelial growth factor, epidermal growth factor, interleukins, keratinocyte growth factor and connective tissue growth factor (Rozman and Bolta, 2007).

Indications and contraindications

PRP is indicated for skin rejuvenation, when used in its role as a mesotherapeutic agent. It can also be used to increase the rapidity of wound healing following ablative laser treatments (Shin, 2012). However, treatment with PRP is contraindicated in patients with skin diseases, cancers, platelet dysfunction and sepsis.

Combination therapy

By combining laser, ultrasound and PRP, aesthetic practitioners are able to provide needle-free PRP to

the skin. In order to create perforations through the skin to the junction of the epidermis and dermis, the patient initially undergoes fractional laser treatment at a low level. Subsequently, PRP is topically applied to the patient's skin and an ultrasound probe is used to force the PRP through the perforations, into the depth of the laser hole. Because the CO₂ laser coagulates at the same time as ablating, there is no build up of blood clot in the column of tissue, enabling the non-invasive application of PRP. In addition, providing PRP in combination with CO₂ laser therapy has been reported to reduce patient recovery time (Lee, 2012).

Case study

Patient history

A 47-year-old woman attended the clinician's clinic with concerns about the quality of her skin. Her main issue was that she had some sun and environmental damage to her skin, and felt her skin had too many dark spots and fine lines. She required skin rejuvenation and her skin was identified as Fitzpatrick type II.

Examination of the patient's skin revealed that it was of a good quality; however, fine lines, wrinkles and heterogenous patches of pigmentation suggestive of sun damage were identified. To quantify the skin damage and provide a baseline measurement for any subsequent monitoring of treatment outcomes, a scan was performed using VISIA (*Figure 1*). The scan showed visible signs of ageing skin and sun damage, which reinforced the patient's desire to rejuvenate her skin.

Treatment

Following the patient's skin assessment, the clinician recommended PRP injections with a laser, or needle-free PRP with a laser. A joint decision was made to provide treatment with needle-free PRP using laser and ultrasound technologies. During the decision-making process, the patient was counselled with full informed consent and time was made available to her to allow for a considered judgement as to whether to proceed with treatment or not. The clinician ensured the patient signed a written consent form for laser treatment and PRP infusion before treating her.

Pain relief

The patient had EMLA cream (lidocaine 2.5% and prilocaine 2.5%) applied to her skin one hour before treatment. EMLA is an effective local anaesthetic that takes approximately 30-60 minutes to work. After taking effect, the EMLA was removed and the patient's skin was thoroughly cleaned in three passes with Tisept Solution (Molnlycke Health Care, Lancashire).

Laser

Fractional ablation treatment was carried out with the Pixel CO₂ Laser (ABC Lasers, Cambridge), which

CASE STUDY ▼




Figure 2: VISIA scan two weeks after the patient's treatment, showing spots, wrinkles, texture, pores, UV spots, brown spots, red areas and porphyrins (from left to right, first row to second row)

was set at high power, 20 mJ/pixel and 7x7 fractional array. Putting this into perspective, the manufacturer recommends settings of high power, 70mJ/pixel and 7x7 fractional array for fine lines and wrinkles. After eye shields were given to the patient to protect her from any undue harm, the patient's full face was treated in one pass.

Platelet-rich plasma and ultrasound

A blood sample was taken using the MyCells (Dublin, Ireland) PRP kit and processed for the harvesting of platelets. The whole plasma layer was applied to the patient's skin topically to ensure all platelets were used together at one time, rather than treating the patient with platelet-rich and platelet-poor layers as separate entities. The PRP was applied by the clinician, who used sterile gloves following thorough skin sterilisation with Tisept Solution.

Although all of the patient's plasma was applied to the skin, only 25% was placed on the skin at each pass of the ultrasound to prevent spillage. The IMPACT ultrasound head (ABC Lasers, Cambridge) was used at 50% for a total of 20 minutes. The clinician performed two passes to each side of the patient's face, where each pass took 5 minutes to complete. Sterility was maintained by placing cling film on the patient's skin at each pass to prevent contact between the ultrasound head and the blood product. Each side of the patient's face was treated separately to avoid both application of the cling film to the whole face at once and prevent airway obstruction.

After care

After the procedure, the patient's skin was cooled down using a skin-cooling device specifically for use following laser treatments, and then aloe vera and a cooling face

mask was applied for 30 minutes. The patient then applied her make-up as normal and went home.

Follow-up

As the laser was only used to create perforations in the skin for the delivery of PRP, the patient's recovery time was only one day. Two weeks following her treatment, the patient returned for a follow-up appointment and a repeat VISIA scan was performed, which showed a significant improvement in the quality of her skin (Table 1; Figure 2). The VISIA scan (Figure 2) highlighted that all aspects of her skin had improved considerably, including the presence and quantity of spots, wrinkles, skin texture, pores, ultraviolet spots, brown spots, red areas and porphyrins.


Not only were results shown objectively by Figure 2, but also the patient reported that her skin was soft, smooth, fresh and had fewer pores.

Discussion

There has been no evidence published previously on the use of fractional CO₂ laser and ultrasound technology to deliver PRP to the skin. PRP is becoming a popular aesthetic treatment for many reasons; for example, patients like the concept of using autologous tissue for skin rejuvenation. Whereas aesthetic practitioners prefer to avoid high capital costs and will use multiple therapies to treat a single patient concern, patients want to avoid post-procedure bruising and the use of needles where possible. In this case report, the clinician avoided multiple injections of PRP by applying it topically, thereby avoiding any risk of bruising.

Fractional CO₂ treatments, however, require adequate training for the therapy itself and managing complications such as infections, burns and delayed wound healing. Although the settings used in this patient's laser treatment were relatively low, the results demonstrated this power output is sufficient enough to allow penetration of PRP into the dermis. The low power has two main effects: to reduce the diameter of the cylinder of tissue ablated by the laser and reduce the depth of penetration of the ablated cylinder.

Conclusion

This case report has shown that needle-free PRP treatments can be used in selected individuals, with the right equipment, to significantly improve skin quality. Although the settings used in the laser treatment were relatively low, the power output is sufficient enough to allow penetration of PRP into the dermis, as demonstrated by the results from treatment. As the laser settings were relatively low, skin erythema only lasted one day, which would be expected with ablative laser treatment. Recovery time was rapid, there was no post-procedure bruising, and the effects were demonstrated by objective and subjective results. 

References

- Alexiades-Armenakas MR, Dover JS, Arndt KA (2008) The spectrum of laser skin resurfacing: nonablative, fractional, and ablative laser resurfacing. *J Am Acad Dermatol* 58(5): 719–37
- Carroll L, Humphreys TR (2006) LASER-tissue interactions. *Clin Dermatol* 24(1): 2–7
- Gold MH (2012) IMPACT: Acoustic-Pressure Ultrasound for the Enhancement of Cosmetic Products for Aesthetic Applications. Alma Lasers White Paper
- Hedelund L, Bjerring P, Egekvist H, Haedersdal M (2006) Ablative versus non-ablative treatment of perioral rhytides. A randomized controlled trial with long-term blinded clinical evaluations and non-invasive measurements. *Lasers Surg Med* 38(2): 129–36
- Issa MC (2013) Effective scar treatment: IMPACT transepidermal delivery. *Prime* 3(2): 104
- Lee JW, Kim BJ, Kim MN, Mun SK (2011) The efficacy of autologous platelet rich plasma combined with ablative carbon dioxide fractional resurfacing for acne scars: a simultaneous split-face trial. *Dermatol Surg* 37(7): 931–8
- Martin P (1997) Wound healing--aiming for perfect skin regeneration. *Science* 276(5309): 75–81
- Newman PG, Rozycki GS (1998) The history of ultrasound. *Surgical Clin North Am* 78(2): 179–95
- Papadavid E, Katsambas A (2003) Lasers for facial rejuvenation: a review. *Int J Dermatol* 42(6): 480–7
- Redaelli A, Romano D, Marcianó A (2010). Face and neck revitalization with platelet-rich plasma (PRP): clinical outcome in a series of 23 consecutively treated patients. *J Drugs Dermatol* 9(5): 466–72
- Ross EV, McKinlay JR, Anderson R (1999). Why does carbon dioxide resurfacing work? A review. *Arch Dermatol* 135(4): 444
- Rozman P, Bolta Z (2007) Use of platelet growth factors in treating wounds and soft-tissue injuries. *Acta Dermatovenerol Alp Panonica Adriat* 16(4): 156
- Shin MK, Lee JH, Lee SJ, Kim, NI (2012) Platelet-rich plasma combined with fractional laser therapy for skin rejuvenation. *Dermatol Surg* 38(4): 623–30

Key points

- ▶ If PRP treatment is clinically indicated and there is a wish to deliver PRP to the skin without the use of injections, this is now possible. PRP can be topically applied to the skin.
- ▶ A CO₂ laser can be used effectively to create multiple skin perforations
- ▶ Through these perforations an appropriate ultrasound device can be used to create pulses which force topically applied PRP into the dermis
- ▶ Skin quality improves both subjectively and objectively using this method